

## Neuropathic orofacial pain: Facts and fiction

Lene Baad-Hansen<sup>1,2</sup> and Rafael Benoliel<sup>3</sup>

Cephalalgia

2017, Vol. 37(7) 670–679

© International Headache Society 2017

Reprints and permissions:

sagepub.co.uk/journalsPermissions.nav

DOI: 10.1177/0333102417706310

journals.sagepub.com/home/cep



### Abstract

**Definition and taxonomy:** This review deals with neuropathic pain of traumatic origin affecting the trigeminal nerve, i.e. painful post-traumatic trigeminal neuropathy (PTTN).

**Symptomatology:** The clinical characteristics of PTTN vary considerably, partly due to the type and extent of injury. Symptoms involve combinations of spontaneous and evoked pain and of positive and negative somatosensory signs. These patients are at risk of going through unnecessary dental/surgical procedures in the attempt to eradicate the cause of the pain, due to the fact that most dentists only rarely encounter PTTN.

**Epidemiology:** Overall, approximately 3% of patients with trigeminal nerve injuries develop PTTN. Patients are most often female above the age of 45 years, and both physical and psychological comorbidities are common.

**Pathophysiology:** PTTN shares many pathophysiological mechanisms with other peripheral neuropathic pain conditions.

**Diagnostic considerations:** PTTN may be confused with one of the regional neuralgias or other orofacial pain conditions. For intraoral PTTN, early stages are often misdiagnosed as odontogenic pain.

**Pain management:** Management of PTTN generally follows recommendations for peripheral neuropathic pain.

**Expert opinion:** International consensus on classification and taxonomy is urgently needed in order to advance the field related to this condition.

### Keywords

Painful post-traumatic trigeminal neuralgia (PTTN), atypical odontalgia, neuropathic pain, orofacial pain

Date received: 16 January 2017; revised: 23 March 2017; accepted: 31 March 2017

### Definition and taxonomy

This review deals primarily with the taxonomy, symptomatology, epidemiology, pathophysiology, diagnosis and management of the condition termed painful post-traumatic trigeminal neuropathy (PTTN) as defined (Section 13.1.2.3) in the International Classification of Headache Disorders (ICHD-3 beta) published in 2013 (1). In addition, we will review related entities such as atypical odontalgia (AO) (2), an orofacial pain condition without well-established diagnostic criteria and with significant gaps in the understanding of its pathophysiology. Originally, diagnostic criteria for AO did not include the evaluation of signs of nerve damage even though the condition was hypothesized to be neuropathic (2–7). However, at present, many consider AO as a subform of persistent idiopathic facial pain (PIFP) (ICHD 13.11), where sensory disturbances have been excluded and a neuropathic background is therefore unlikely in such patients (1). Thus, it is

important to distinguish between “early criteria” AO (subsequently referred to as *early criteria AO*) (2) and “PIFP subform” AO (1). For the latter, the reader is referred to the article by Gaul and Benoliel in the present issue of *Cephalalgia*. The Classification of Chronic Pain by the International Association for the Study of Pain (IASP) is discussing the terminology for the

<sup>1</sup>Section of Orofacial Pain and Jaw Function, Department of Dentistry and Oral Health, Aarhus University, Aarhus, Denmark

<sup>2</sup>Scandinavian Center for Orofacial Neurosciences (SCON), Denmark/Sweden

<sup>3</sup>Rutgers School of Dental Medicine, Rutgers State University of New Jersey, Newark, NJ, USA

### Corresponding author:

Lene Baad-Hansen, Section of Orofacial Pain and Jaw Function, Department of Dentistry and Oral Health, Aarhus University, Vennelyst Boulevard 9, DK-8000 Aarhus C, Denmark.

Email: lene.hansen@dent.au.dk

primary chronic intraoral pain counterpart of PIFP (8). Importantly, a majority of patients with early criteria AO have localized disturbances in somatosensory function consistent with the involvement of neuropathic pain mechanisms (2–6). It has therefore been proposed that this subset of early criteria AO patients may in fact represent an intraoral painful post-traumatic trigeminal neuropathy (PTTN) (6).

PTTN is the most recent term proposed by the International Headache Society (IHS) to reflect neuropathic pain of traumatic origin affecting the trigeminal nerve. This term replaces previously used terms such as deafferentation pain, traumatic neuropathy, phantom tooth pain and, in part, early criteria AO (2,5,6,9–19). It is important to emphasize that this term describes a painful neuropathy in all parts of the head, including the face and oral cavity. There are therefore a wide range of PTTN presentations due to trauma around the external parts of the head and intraorally (20–22). The extraoral presentations of PTTN are usually straightforward, with a clear history of trauma and the classical signs and symptoms of a painful traumatic neuropathy (see below). The intraoral counterpart is often a more complex diagnosis, and we will therefore focus more on this location. However, the symptomatology and treatment approach are exactly the same.

Some researchers have suggested renaming early criteria AO as ‘persistent dentoalveolar pain’ (PDAP) (23) but this term has not yet been adopted into major classifications. The PDAP term was originally suggested to include both a primary and a secondary subtype, with the secondary type starting “in close temporal relationship with a causal event”, i.e. secondary to, for example, nerve injury (23). Also, secondary PDAP

was suggested to include two subforms, one with and one without sensory disturbances (23). This means that there is a significant degree of overlap between PTTN and “secondary PDAP”, which is problematic in our view. Therefore, to limit the risk of confusion, we will for the remaining part of this review use the term PTTN to cover PTTN and early criteria AO, as well as secondary PDAP.

Trigeminal neuralgia, glossopharyngeal neuralgia and occipital neuralgia, as well as PIFP, are covered in other articles in this special issue of *Cephalalgia*.

### Diagnostic criteria

The latest diagnostic criteria for PTTN, together with the early diagnostic criteria for AO for comparison, are shown in Table 1 (1). The early criteria for AO are clearly very broad and, theoretically, could include pain of neuropathic, neurovascular or indeterminate origin (18). Intraoral PTTN often occurs in close temporal relationship with invasive dental procedures (5,6,13,15,24). However, it is a complicating matter that pain may also have been present before the invasive procedure leading to nerve damage. The pain site in intraoral PTTN is often well localized and can include any tooth or extraction site, but the pain may move from tooth to tooth following dental procedures (15). Somatosensory changes in early criteria AO patients have been reported in several studies, indicating that a significant proportion of these patients qualify for a PTTN diagnosis according to current criteria. However, we recognize that a subgroup of such patients, with similar symptoms, may not have neuropathic pain and may instead be suffering from primary

**Table 1.** Comparison of diagnostic criteria for painful post-traumatic trigeminal neuropathy and early criteria for atypical odontalgia.

IHS criteria for Painful Post-traumatic Trigeminal Neuropathy (PTTN) (1)	Early criteria for atypical odontalgia (AO) (2,3)
(a) Unilateral facial and/or oral pain fulfilling criterion C.	1. Pain in a tooth or persistent pain after tooth extraction with no signs of pathology on clinical and radiographic examinations.
(b) History of an identifiable traumatic event to the trigeminal nerve, with clinically evident positive (hyperalgesia, allodynia) and/or negative (hypoesthesia, hypoalgesia) signs of trigeminal nerve dysfunction.	2. Pain has been ongoing for at least six months.
(c) Evidence of causation demonstrated by both of the following:	3. Pain is present every day, most of the day.
1. Pain is located in the distribution of the same trigeminal nerve.	4. Pain is non-paroxysmal.
2. Pain has developed within 3–6 months of the traumatic event.	Other factors that are often associated: Allodynia and unreliable effect of local anesthesia.
D. Not better accounted for by another ICHD-3 diagnosis.	

chronic pain (4,6,15,19,25,26). Also, we acknowledge that it is a challenge to clearly separate primary chronic pain patients from PTTN patients due to overlaps in symptomatology.

## Symptomatology

The clinical characteristics of PTTN vary considerably, most likely due to a combination of environmental, psychosocial and genetic factors (20,27). Possibly the type and extent of injury may influence the incidence and characteristics of PTTN. The clinical phenotype may thus involve combinations of spontaneous and evoked pain and of positive (e.g. dysesthesia) and negative symptomatology (e.g. numbness) (6,20,27,28).

PTTN typically occurs in the area of the injury, or the distal dermatome of the affected nerve (20). Sensory dysfunction is clinically detectable, particularly when a major nerve branch is involved (20). However, in purely intraoral PTTN, sensory disturbances are not always detectable with simple chair-side sensory testing but require performance of more comprehensive tests, for example quantitative sensory testing (QST) (6,28). For major nerve branch injuries, severe allodynia may be present (18,29). Hyperalgesia and other sensory changes may be found also in extratrigeminal sites in a subset of patients, suggesting more extensive alterations in central somatosensory processing (6,26). Thermal modalities are often preserved (26,30).

PTTN pain is unilateral (20) and rarely, if ever, crosses the midline (18). Over time, PTTN may in some cases become more diffusely distributed. Contralateral sensory signs have been demonstrated in patients with PTTN (31), suggesting bilateral involvement of the central nervous system. Pain is of moderate to severe intensity (VAS 5–8) and is usually described as burning or shooting, but other descriptors may also be used (18,28,32–34,37). PTTN is characteristically continuous, lasting most of the day, and present on most days (20). Paroxysmal pain may be spontaneous or initiated by touch or function (18,29). Patients may complain of swelling (not always verifiable clinically), a foreign body, heat or cold, local redness or flushing (20,29,35).

A common feature of patients with intraoral PTTN is that they often have a history of multiple and repeated consultations with different specialists and have received various treatments, including repeated invasive procedures bearing a great risk of symptom aggravation (15,36,37). They have a history of multiple treatment modalities aimed at eliminating pain, often including pharmacotherapy, occlusal adjustments and surgery (34). In particular, these patients may be at risk of going through unnecessary dental and oral surgical procedures in an attempt to eradicate the cause of the

pain. This is possibly due to the fact that most dentists only rarely encounter PTTN, and may therefore suspect it only late in the course of the condition. As a further complicating matter for proper diagnosis and management, a significant proportion of these patients suffer from psychological and other comorbidities (37). In fact, a few decades ago, many researchers and clinicians hypothesized these pain conditions to be of psychogenic origin (14), however this hypothesis has not been supported by scientific evidence.

## Epidemiology

In general, good estimates of the prevalence of PTTN are lacking, probably at least in part due to shifting diagnostic terms and criteria. Importantly, traumatic injuries to the trigeminal nerve only rarely lead to a painful neuropathy. Relative to spinal nerves, the trigeminal nerve may show subtle differences in the pathophysiological events that may lead to pain.

In mixed cohorts of extra and intraoral PTTN, patients are usually female (6,20,30,34,38) and onset is typically around 45–50 years. PTTN is associated with a substantial psychosocial burden (5,15,34,37,39). PTTN patients with more severe pain demonstrate elevated levels of depression and pain catastrophizing, as well as substantially reduced quality of life (QoL) and coping levels (38).

The published estimates of prevalence of non-odontogenic tooth pain, of which a large proportion is likely to qualify for a PTTN diagnosis, are that around 3–5% of patients undergoing root canal treatment develop such pain (40,41). This is not different from the estimated prevalence of 3% PTTN following major trauma such as facial fractures (22), so the importance of the degree of trauma is unclear. In a tertiary care series of 183 consecutive patients with trigeminal nerve damage (lingual or inferior alveolar nerve) of different iatrogenic etiologies but mainly third molar surgery, 70% presented with neuropathic pain (29). More females than males in this patient group suffered from neuropathic pain (29). However, this is a study on patients seeking treatment and is likely to be demographically biased.

## Pathophysiology

PTTN may result from a wide variety of nerve injuries, ranging from mild to severe (27). These include external trauma and iatrogenic injuries from dental treatments such as root canal therapies, extractions, oral surgery, dental implants, orthognathic surgery and other invasive procedures (27). Even relatively mild interventions such as local anesthetic injections may induce a non-painful neuropathy and sometimes PTTN.

Local anesthetic-induced neuropathy is considered to be the result of physical trauma and neurotoxic effects of the anesthetic agent (42). Neural damage can induce pain originating in a peripheral nerve (peripheral neuropathy), in a ganglion (ganglionopathy), in a dorsal root (radiculopathy) or from the central nervous system (central neuropathic pain) (27). The focus of this article is on pain resulting from injury to branches of trigeminal neurons, all of which are essentially peripheral.

Animal studies suggest that the pathophysiology of painful inflammatory or traumatic neuropathies involves a cascade of events in the nervous system. Events are time dependent, progressing from the peripheral to the central nervous system. These include alterations in functional, biochemical and physical characteristics of neurons and glia on a background of genetic makeup (43–50). A central role for the dopamine system and the dopamine D2 receptor has been demonstrated in pain and analgesia on a group of neuropathic pain patients (51). Peripheral sensitization develops rapidly with inflammation associated activation or sensitization of nociceptors. This gives rise to the early clinical signs of hyperalgesia and allodynia. Following injury some neurons may die; however, others survive with attempts at healing that may involve disorganized sprouting of nerve fibers. These eventually form a neuroma that acts as an ectopic center for neurophysiological activity and increases nociceptive input. Additionally, ectopic activity has been reported in the cell bodies of injured neurons (dorsal root or trigeminal ganglion). Catalyzed by inflammation A $\beta$  fibers, which usually transmit innocuous stimuli only, they undergo a phenotypic change and express substance-P (48). Thus, A $\beta$  fibers are able to induce painful sensations in response to peripheral stimulation, and may be one explanation for the phenomenon of allodynia. Central changes are induced by persistent activity in afferents that is transmitted to the central nervous system (CNS). This increasingly sensitizes the CNS, resulting in amplified responses: a phenomenon termed “wind up”. These changes may spread and induce activation of adjacent areas in the CNS, resulting in central sensitization. Further changes in the CNS, such as death of inhibitory interneurons, increased facilitatory and decreased inhibitory activity of CNS centers, induce a pronociceptive state. Reduced levels of conditioned pain modulation have been shown in patients with PTTN (52).

Considering the number of invasive procedures performed daily in the oral cavity, it is no surprise that despite the low incidence figures, these patients are commonly seen. Indeed, in humans, intraoral PTTN has, in the majority of cases, been suggested to be the result of injury to trigeminal primary afferent fibers due

to dental procedures such as root canal treatment or tooth extraction (15). Further supporting this, animal studies have shown that loss of tooth pulp in an inflamed environment results in a derangement in the periodontal nerve plexus with disorganized axonal sprouting and neuroma formation (15,53).

Quantitative sensory testing (QST) studies have demonstrated multiple somatosensory abnormalities in PTTN patients (4,6,15,19,25,26,54). However, as for neuropathic pain in general as well as PTTN specifically, no pathognomonic QST somatosensory profile exists (6,20,55). Thus, QST may reveal both loss and gain of somatosensory function in such patients (6,21,22). In intraoral PTTN it is a common clinical finding that the patients are not aware of their somatosensory abnormality, as the affected intraoral area may be quite small in comparison with patients with larger trigeminal nerve injuries. However, there is a lack of studies with actual mapping of areas exhibiting somatosensory dysfunction in such patients. The so-called ‘nociceptive-specific’ human blink reflex (BR) is reduced and delayed at group level in PTTN patients compared with healthy matched controls (56), indicating possible impairment of nerve function. However, the BR responses from stimulation of both painful and non-painful sides in these patients are abnormal, which supports involvement of central nervous system mechanisms (15,56). In the same study, endogenous pain inhibition was not found to be abnormal in intraoral PTTN patients (56), in contrast with the study mentioned earlier using other diagnostic criteria (52). In a QST study, a subgroup of around 7% of patients has been reported to have both trigeminal and extratrigeminal somatosensory dysfunction as demonstrated by QST (6), indicating that such patients may indeed suffer from a more generalized pain problem, and the signs of somatosensory dysfunction intraorally may thus not be due to neuropathic pain but rather to a form of primary chronic pain, neuroplastic or functional/dysfunctional pain (8,57). Pharmacological studies in PTTN have demonstrated that the response to injection of a local anesthetic is equivocal (58), that it does not seem to respond to i.v. fentanyl or S-ketamine (4), and that some patients respond to sympathetic blockade (uncontrolled study) (59). The findings from the local anesthetic study indicated that PTTN is not solely dependent on peripheral afferent input, but that sensitization of higher order neurons may be involved (15,58). The i.v. study indicated that opioids or N-Methyl-D-Aspartate (NMDA) receptors do not seem to play a major role in the pathophysiology (4). Finally, the sympathetic block findings have not yet been repeated in a randomized controlled fashion, and firm conclusions on the basis of that study is therefore not possible at present. At the preclinical level, it is



interesting that the typical sympathetic sprouting seen in lumbar dorsal root ganglions following trauma to the sciatic nerve has not been observed in the trigeminal nerve (60,61) and sympathectomy does not affect the level of ectopic discharge in damaged trigeminal neurons (62). Whilst the translational significance of this is unclear, it supports the clinical observation that sympathetic involvement in PTTN is extremely rare.

In addition, ectopic neuroma firing from axotomized infraorbital nerves is lower than in sciatic nerves (63) and the incidence of clinical PTTN seems lower than that in spinal nerves (22) suggesting that the trigeminal system may possess some unique, as yet unclear, attributes.

### Diagnostic considerations

At present, PTTN diagnosis is, like all other IHS diagnoses, based primarily on signs and symptoms, which are sometimes combined with evidence of disease, structural damage or injury (64). PTTN may be confused with one of the regional neuralgias although the history, signs and symptoms should allow accurate diagnosis. Specifically, extraoral PTTN should be a relatively straightforward diagnosis when trauma is documented and, for example, a scar is visible. We have observed cases of PTTN following invasive procedures in the facial region (maxillary sinus surgery) where the diagnosis is more complex, since there may be no external signs to rely on. Intraorally, the process may be even more complex and relevant differential diagnoses would include odontogenic pain, referred pain from surrounding structures such as the maxillary sinus or masticatory muscles or chronic primary pain. The possible consequences of an erroneous diagnosis are numerous, e.g. the patient may suffer longer than necessary, or the patient may be subjected to pointless invasive, expensive and potentially harmful procedures, such as endodontic treatments, tooth extractions or oral or sinus surgery. The diagnostic process relies on a thorough medical and dental history, a clinical intraoral and extraoral examination and, if necessary, supplementary diagnostic tests. Ideally, a non-invasive, cheap and error-free gold standard diagnostic test should be available, which is not the case for PTTN. Instead, the field relies on reference standards described on the basis of consensus among experts, as in the case of temporomandibular disorders (TMD) (65). A reference standard diagnostic test for PTTN has not yet been established but some of the tests mentioned below may be suggested as elements in one.

The demonstration of trigeminal nerve dysfunction is essential for the diagnosis of PTTN according to the diagnostic criteria. In case of damage to a larger branch of the trigeminal nerve with clear and neuro-anatomically relevant sensory disturbances, the

diagnosis may seem rather straightforward. However, other cases with less pronounced sensory disturbances may require extensive testing of somatosensory function to demonstrate a lesion, lending support for a diagnosis of PTTN.

For neuropathic pain in general, a useful grading system has been published and recently revised (66,67). This grading system lists requirements to be able to describe a pain as *possible*, *probable* or *definite* neuropathic pain (67). An important part of such a grading is the demonstration of somatosensory changes within the painful area. Numerous qualitative and quantitative psychophysical techniques have been proposed and used in the description of orofacial somatosensory function and the specific selection of technique includes time considerations, among other things, because the most reliable and accurate methods require multiple repetitions of stimuli (68). Standardization of both screening and comprehensive psychophysical tests is recommended as an essential way to improve the diagnostic accuracy and facilitate the understanding of neural mechanisms and somatosensory changes in different orofacial pain conditions, and it may also help to guide management (68). The range of available instruments includes sophisticated thermal, mechanical and electrical systems able to assess relevant thresholds and suprathreshold responses so that both gross clinical and advanced neurophysiologic techniques may be used to detect, quantify and monitor sensory deficits or changes (69–74). These are, however, expensive and as stated, time consuming. A basic bed/chairside examination may be performed with relatively simple equipment relying on thermal (ice, hot implements) and mechanical (pinprick, cotton wool, calibrated monofilaments) stimuli (68,75). However, numerous factors may shape the psychophysical output response, for example, the verbal instructions to the patient, age, gender, attention, drowsiness, mood, cognitive function, ongoing litigation, psychological distress and patient cooperation (68,74,76,77). Also, in order for the test to be able to aid in distinguishing accurately between different pain conditions, more systematic studies that compare psychophysical test results between relevant diagnoses are needed.

Apart from psychophysical tests, neurophysiological tests such as brain stem reflexes may be useful in terms of demonstration of somatosensory dysfunction. Brain stem reflexes are used to test somatosensory function by testing the functional integrity of cranial nerve afferents and efferent pathways and to help identify and localize lesions or dysfunction of the reflex loops or the central systems that control them (78). One example is the trigemino-facial blink reflex, which can be evoked by laser, mechanical or electrical stimulation (56,79–81). The blink reflex is not advocated as a stand-alone

measure in the evaluation of somatosensory function, but rather as part of a comprehensive work-up including both QST and neurophysiological tests (15). Other neurophysiological techniques such as evaluations of sensory nerve action potentials (SNAPs) are also available (82,83).

It is important for classification of orofacial pain conditions to be aligned with and integrated in pain classification systems covering the entire body, including the orofacial region (8). Therefore, should overall diagnostic criteria for neuropathic pain be slightly revised in the coming revision of the IASP classification of chronic pain (8,67), the diagnostic criteria for PTTN should obviously follow.

### Pain management

In general, early intervention is considered important for all kinds of pain management to avoid or reduce the risk of chronification. However, there is not much scientific evidence to support this for PTTN.

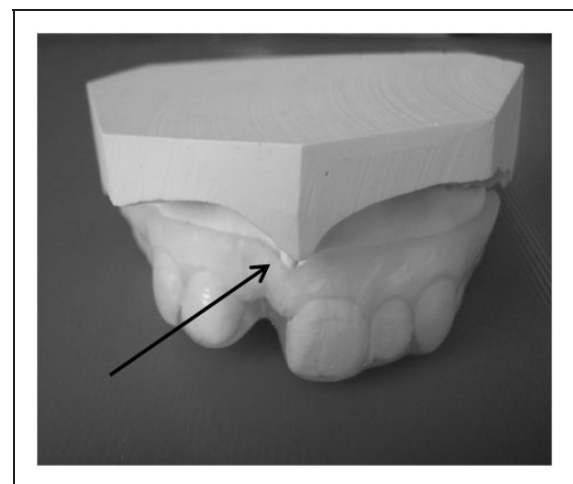
Early management of nerve injury should be aimed at controlling associated inflammation, considered one of the initiators of neuropathic pain. Steroids may be warranted (prednisone 40–60 mg initially then tapered over 7–10 days, dexamethasone 12–16 mg initially then similarly tapered). Tapering is aimed at reducing side effects from consistently high dosages and is not always essential. In support, animal studies show that early treatment with dexamethasone relieves neuropathic pain (84), but there is no evidence from clinical studies.

Damage to a larger nerve trunk may be suitable for surgical repair of the defect. Early intervention provides the best chances of regaining lost sensation (31). Whether the early surgical repair affects the risk of developing PTTN, however, is currently unknown (31). Regarding nerve damage not suitable for surgical repair, it is unclear how quickly there may be healing and regained function, if at all. There seems to be little evidence, but clinical experience has led to the widely-held belief that this should occur within the first 12–18 months. After that, the condition may be considered beyond the hope of spontaneous recovery. In patients with a permanent neurological deficit, some may remain with a non-painful neuropathy and others may develop PTTN. In such cases, further management consists first of thorough patient education, where the patient receives information on the diagnosis, and the fact that further invasive procedures with the purpose of relieving the PTTN pain will not be helpful and bear a risk of worsening the nerve damage and/or the pain.

In the majority of PTTN cases, where the likelihood of providing a cure is low, a palliative approach based

on the recommendations for management of peripheral neuropathic pain conditions (85–87) may be applied. Randomized clinical trials in well-characterized patients with PTTN are lacking. A topical approach may be useful in some cases (3,32). In the case of extraoral PTTN, topical application of local anesthetics (LA) or capsaicin may also be performed (32) but it is essential to avoid contact with the eyes. Commercially available LA and capsaicin patches are also available and may be more comfortable to apply. Although the 8% capsaicin patch (Qutenza) has been successfully applied to treatment of a trigeminal neuropathy it is not currently approved for use in the face due to the very high concentration and the close vicinity of mucosa (eye, oral cavity). Intraorally, some regions may be suitable for topical applications also, for example through fabrication of a so-called neurostent, i.e. a custom-made soft splint designed to cover the painful area (see Figure 1). Such a neurostent allows for application of LA or capsaicin or a mixture thereof under occlusion without risking spread of the compounds to the rest of the oral cavity and pharynx. No official recommendations for concentrations of LA or capsaicin for intraoral use exist at this moment but for capsaicin, a concentration of 0.1% is probably the maximum to avoid too much pain from the application. For LA, commercially available lidocaine gels or creams may be used.

If a topical approach is not possible or effective, systemic medications for peripheral neuropathic pain may be applied. Such medications include tricyclic antidepressants (TCA), selective noradrenalin reuptake inhibitors (SNRIs), gabapentin, pregabalin, other



**Figure 1.** Soft splint (neurostent) designed for intraoral topical application of local anesthetics or capsaicin under occlusion. Arrow indicates painful region covered by the neurostent.

anticonvulsants or opioids (86–88). In comparison with other neuropathic pains like postherpetic neuralgia, painful diabetic neuropathy, and painful spinal traumatic neuropathies with a drug response rate in the range of 20–40%, response rates in PTTN are reported to be lower, around 11% (36). Approximately one in three patients abandon drug treatment, mainly due to adverse effects (36,89). In contrast, the initial response rate for pharmacological management of classical trigeminal neuralgia is around 70–90% (90), although with significant side effects (36). What is interesting is that the drugs successful for trigeminal neuralgia are largely ineffective in PTTN. Additionally, while neurosurgical options are available for classical trigeminal neuralgia, they are essentially contraindicated or unsuccessful in PTTN (32,36).

Psychological, cognitive behavioral approaches and hypnosis may also be useful (32,91). Unfortunately, there is a paucity of studies assessing the long-term prognosis of PTTN (32,36). A seven-year follow-up study on 37 early criteria AO patients, of whom some met the present criteria for PTTN, indicated that 35% of patients reported overall pain relief, whereas the majority reported similar levels of pain at follow-up (34).

### Expert opinion: Open questions and burning desires

As is clear from this article, firm consensus regarding diagnosis and classification of PTTN has yet to be obtained. The PTTN terminology was only recently described (9) and was first introduced into the IHS classification in 2013 (1). Likewise, the latest definition of neuropathic pain from the IASP is less than a decade old (8,66). In addition, the degree of certainty of a diagnosis of neuropathic pain may vary according to availability of tests of somatosensory function, and grading systems for diagnostic certainty have also been slightly

revised over the last decade (66,67). These issues mean that different studies conducted over the years are not directly comparable, and earlier findings are likely not generalizable between patient populations diagnosed using different criteria and definitions. A diagnostic gold standard or reference standard for PTTN diagnosis is currently missing, but should be developed. With this, further diagnostic tests could be developed and tested against such a standard. Ideally, the future will bring simple, quick, inexpensive and valid diagnostic tests that may be used in future studies on prevention, prediction and management of PTTN. First of all though, consensus on classification and taxonomy is the basis that all future studies need to be based on.

### Expert opinion: Where the field would need to go

The field should progress in a structured fashion, beginning with agreement on and universal implementation of the IHS criteria for PTTN. Studies on intra and extraoral PTTN should rely on these criteria and examine demographic, environmental, psychological and genetic data on specific phenotypes. Prospective studies need to examine the natural history of PTTN from the time of injury through healing and possible development of pain and its treatment; it would be invaluable to be able to predict which of our patients are at risk and what preventative therapies are best. Along the prevention avenue, good education and training of dental and surgical colleagues is important, so that the number of iatrogenic nerve injuries can be as limited as possible and unnecessary invasive procedures are avoided completely. Additionally, RCTs to establish preferred drugs may improve treatment outcomes. Clearly, we are in desperate need of more efficient and safer drugs to treat traumatic neuropathies. This requires a concerted effort to identify novel drug targets at the preclinical level.

### Article highlights

- Painful post-traumatic trigeminal neuropathy (PTTN) is the latest term for trigeminal neuropathic pain of traumatic origin.
- PTTN may be confused with one of the regional neuralgias or other orofacial pain conditions.
- Complete international consensus on classification and taxonomy is needed.
- A diagnostic reference standard for PTTN diagnosis should be developed.
- The majority of patients formerly referred to as having atypical odontalgia qualify for a PTTN diagnosis.
- Management of PTTN pain should follow recommendations for peripheral neuropathic pain.

### Declaration of conflicting interests

The authors declared no potential conflicts of interest with respect to the research, authorship, and/or publication of this article.

### Funding

The authors received no financial support for the research, authorship, and/or publication of this article.

## References

- Headache Classification Committee of the International Headache Society (IHS). The International Classification of Headache Disorders, 3rd edition (beta version). *Cephalalgia* 2013; 33: 629–808.
- Woda A and Pionchon P. A unified concept of idiopathic orofacial pain: Clinical features. *J Orofac Pain* 1999; 13: 172–184.
- Melis M, Lobo SL, Ceneviz C, et al. Atypical odontalgia: A review of the literature. *Headache* 2003; 43: 1060–1074.
- Baad-Hansen L, Juhl GI, Jensen TS, et al. Differential effect of intravenous S-ketamine and fentanyl on atypical odontalgia and capsaicin-evoked pain. *Pain* 2007; 129: 46–54.
- Baad-Hansen L. Atypical odontalgia – pathophysiology and clinical management. *J Oral Rehabil* 2008; 35: 1–11.
- Baad-Hansen L, Pigg M, Ivanovic SE, et al. Intraoral somatosensory abnormalities in patients with atypical odontalgia – a controlled multicenter quantitative sensory testing study. *Pain* 2013; 154: 1287–1294.
- Graff-Radford SB and Solberg WK. Atypical odontalgia. *J Craniomandib Disord* 1991; 6: 260–265.
- Treede RD, Rief W, Barke A, et al. A classification of chronic pain for ICD-11. *Pain* 2015; 156: 1003–1007.
- Marbach JJ. Phantom tooth pain: Differential diagnosis and treatment. *N Y State Dent J* 1993; 59: 28–33.
- Marbach JJ. Phantom tooth pain: Deafferentation pain. *Pa Dent J* 1984; 51: 32–33.
- Marbach JJ and Raphael KG. Phantom tooth pain: A new look at an old dilemma. *Pain Med* 2000; 1: 68–77.
- Clark GT. Persistent orofacial pain, atypical odontalgia, and phantom tooth pain: When are they neuropathic disorders? *J Calif Dent Assoc* 2006; 34: 599–609.
- Turp JC. Atypical odontalgia – a little known phantom pain. *Schmerz* 2001; 15: 59–64.
- Brooke RI. Atypical odontalgia. A report of twenty-two cases. *Oral Surg Oral Med Oral Pathol* 1980; 49: 196–199.
- Forssell H, Jääskeläinen S, List T, et al. An update on pathophysiological mechanisms related to idiopathic orofacial pain conditions with implications for management. *J Oral Rehabil* 2014; 42: 300–322.
- Reik L Jr. Atypical odontalgia: A localized form of atypical facial pain. *Headache* 1984; 24: 222–224.
- Melis M and Secci S. Diagnosis and treatment of atypical odontalgia: A review of the literature and two case reports. *J Contemp Dent Pract* 2007; 8: 81–89.
- Woda A, Tubert-Jeannin S, Bouhassira D, et al. Towards a new taxonomy of idiopathic orofacial pain. *Pain* 2005; 116: 396–406.
- Zagury JG, Eliav E, Heir GM, et al. Prolonged gingival cold allodynia: A novel finding in patients with atypical odontalgia. *Oral Surg Oral Med Oral Pathol Oral Radiol Endod* 2011; 111: 312–319.
- Benoliel R, Zadik Y, Eliav E, et al. Peripheral painful traumatic trigeminal neuropathy: Clinical features in 91 cases and proposal of novel diagnostic criteria. *J Orofac Pain* 2012; 26: 49–58.
- Benoliel R, Eliav E, Elishoov H, et al. Diagnosis and treatment of persistent pain after trauma to the head and neck. *J Oral Maxillofac Surg* 1994; 52: 1138–1147 (discussion 1147–1148).
- Benoliel R, Birenboim R, Regev E, et al. Neurosensory changes in the infraorbital nerve following zygomatic fractures. *Oral Surg Oral Med Oral Pathol Oral Radiol Endod* 2005; 99: 657–665.
- Nixdorf DR, Drangsholt MT, Ettlin DA, et al. Classifying orofacial pains: A new proposal of taxonomy based on ontology. *J Oral Rehabil* 2012; 39: 161–169.
- Matwychuk MJ. Diagnostic challenges of neuropathic tooth pain. *J Can Dent Assoc* 2004; 70: 542–546.
- Baad-Hansen L, List T, Jensen TS, et al. Increased pain sensitivity to intraoral capsaicin in patients with atypical odontalgia. *J Orofac Pain* 2006; 20: 107–114.
- List T, Leijon G and Svensson P. Somatosensory abnormalities in atypical odontalgia: A case-control study. *Pain* 2008; 139: 333–341.
- Rafael B, Sorin T and Eli E. Painful traumatic trigeminal neuropathy. *Oral Maxillofac Surg Clin North Am* 2016; 28: 371–380.
- Baad-Hansen L, Pigg M, Ivanovic SE, et al. Chairside intraoral qualitative somatosensory testing: Reliability and comparison between patients with atypical odontalgia and healthy controls. *J Orofac Pain* 2013; 27: 165–170.
- Renton T and Yilmaz Z. Profiling of patients presenting with posttraumatic neuropathy of the trigeminal nerve. *J Orofac Pain* 2011; 25: 333–344.
- Siqueira SR, Siviero M, Alvarez FK, et al. Quantitative sensory testing in trigeminal traumatic neuropathic pain and persistent idiopathic facial pain. *Arq Neuropsiquiatr* 2013; 71: 174–179.
- Jääskeläinen SK, Teerijoki-Oksa T and Forssell H. Neurophysiologic and quantitative sensory testing in the diagnosis of trigeminal neuropathy and neuropathic pain. *Pain* 2005; 117: 349–357.
- Renton T and Yilmaz Z. Managing iatrogenic trigeminal nerve injury: A case series and review of the literature. *Int J Oral Maxillofac Surg* 2012; 41: 629–637.
- Renton T, Yilmaz Z and Gaballah K. Evaluation of trigeminal nerve injuries in relation to third molar surgery in a prospective patient cohort. Recommendations for prevention. *Int J Oral Maxillofac Surg* 2012; 41: 1509–1518.
- Pigg M, Svensson P, Drangsholt M, et al. Seven-year follow-up of patients diagnosed with atypical odontalgia: A prospective study. *J Orofac Pain* 2013; 27: 151–164.
- Dagsdottir LK, Skyt I, Vase L, et al. Reports of perceptual distortion of the face are common in patients with different types of chronic orofacial pain. *J Oral Rehabil* 2016; 43: 409–416.
- Haviv Y, Zadik Y, Sharav Y, et al. Painful traumatic trigeminal neuropathy: An open study on the pharmacotherapeutic response to stepped treatment. *J Oral Facial Pain Headache* 2014; 28: 52–60.
- Baad-Hansen L, Leijon G, Svensson P, et al. Comparison of clinical findings and psychosocial factors in patients



- with atypical odontalgia and temporomandibular disorders. *J Orofac Pain* 2008; 22: 7–14.
38. Penarrocha MA, Penarrocha D, Bagan JV, et al. Post-traumatic trigeminal neuropathy. A study of 63 cases. *Med Oral Patol Oral Cir Bucal* 2012; 17: e297–300.
  39. Smith JG, Elias LA, Yilmaz Z, et al. The psychosocial and affective burden of posttraumatic neuropathy following injuries to the trigeminal nerve. *J Orofac Pain* 2013; 27: 293–303.
  40. Nixdorf DR, Moana-Filho EJ, Law AS, et al. Frequency of nonodontogenic pain after endodontic therapy: A systematic review and meta-analysis. *J Endod* 2010; 36: 1494–1498.
  41. Marbach JJ. Is phantom tooth pain a deafferentation (neuropathic) syndrome? Part I: Evidence derived from pathophysiology and treatment. *Oral Surg Oral Med Oral Pathol* 1993; 75: 95–105.
  42. Hillerup S, Jensen RH and Ersboll BK. Trigeminal nerve injury associated with injection of local anesthetics: Needle lesion or neurotoxicity? *J Am Dent Assoc* 2011; 142: 531–539.
  43. Salter MW. Deepening understanding of the neural substrates of chronic pain. *Brain* 2014; 137: 651–653.
  44. Woolf CJ and Salter MW. Neuronal plasticity: Increasing the gain in pain. *Science* 2000; 288: 1765–1769.
  45. Salter MW and Beggs S. Sublime microglia: Expanding roles for the guardians of the CNS. *Cell* 2014; 158: 15–24.
  46. Mogil JS. Pain genetics: Past, present and future. *Trends Genet* 2012; 28: 258–266.
  47. Devor M. Ectopic discharge in Abeta afferents as a source of neuropathic pain. *Exp Brain Res* 2009; 196: 115–128.
  48. Nitzan-Luques A, Devor M and Tal M. Genotype-selective phenotypic switch in primary afferent neurons contributes to neuropathic pain. *Pain* 2011; 152: 2413–2426.
  49. von Hehn CA, Baron R and Woolf CJ. Deconstructing the neuropathic pain phenotype to reveal neural mechanisms. *Neuron* 2012; 73: 638–652.
  50. Lee MC and Tracey I. Imaging pain: A potent means for investigating pain mechanisms in patients. *Br J Anaesth* 2013; 111: 64–72.
  51. Jääskeläinen SK, Lindholm P, Valmunen T, et al. Variation in the dopamine D2 receptor gene plays a key role in human pain and its modulation by transcranial magnetic stimulation. *Pain* 2014; 155: 2180–2187.
  52. Nasri-Heir C, Khan J, Benoliel R, et al. Altered pain modulation in patients with persistent postendodontic pain. *Pain* 2015; 156: 2032–2041.
  53. Holland GR. Periapical neural changes after pulpectomy. *Oral Surg Oral Med Oral Pathol Oral Radiol Endod* 1995; 80: 726–734.
  54. Baad-Hansen L, Abrahamsen R, Zachariae R, et al. Somatosensory sensitivity in patients with persistent idiopathic orofacial pain is associated with pain relief from hypnosis and relaxation. *Clin J Pain* 2013; 29: 518–526.
  55. Maier C, Baron R, Tolle TR, et al. Quantitative sensory testing in the German Research Network on Neuropathic Pain (DFNS): Somatosensory abnormalities in 1236 patients with different neuropathic pain syndromes. *Pain* 2010; 150: 439–450.
  56. Baad-Hansen L, List T, Kaube H, et al. Blink reflexes in patients with atypical odontalgia and matched healthy controls. *Exp Brain Res* 2006; 172: 498–506.
  57. Woolf CJ, Bennett GJ, Doherty M, et al. Towards a mechanism-based classification of pain? *Pain* 1998; 77: 227–229.
  58. List T, Leijon G, Helkimo M, et al. Effect of local anesthesia on atypical odontalgia – a randomized controlled trial. *Pain* 2006; 122: 306–314.
  59. Vickers ER, Cousins MJ, Walker S, et al. Analysis of 50 patients with atypical odontalgia. A preliminary report on pharmacological procedures for diagnosis and treatment. *Oral Surg Oral Med Oral Pathol Oral Radiol Endod* 1998; 85: 24–32.
  60. Benoliel R, Eliav E and Tal M. No sympathetic nerve sprouting in rat trigeminal ganglion following painful and non-painful infraorbital nerve neuropathy. *Neurosci Lett* 2001; 297: 151–154.
  61. Bongenhillem U, Boissonade FM, Westermark A, et al. Sympathetic nerve sprouting fails to occur in the trigeminal ganglion after peripheral nerve injury in the rat. *Pain* 1999; 82: 283–288.
  62. Bongenhillem U, Yates JM, Fried K, et al. Sympathectomy does not affect the early ectopic discharge from myelinated fibres in ferret inferior alveolar nerve neuromas. *Neurosci Lett* 1998; 245: 89–92.
  63. Tal M and Devor M. Ectopic discharge in injured nerves: Comparison of trigeminal and somatic afferents. *Brain Res* 1992; 579: 148–151.
  64. Cruz-Almeida Y and Fillingim RB. Can quantitative sensory testing move us closer to mechanism-based pain management? *Pain Med* 2014; 15: 61–72.
  65. Schiffman E, Ohrbach R, Truelove E, et al. Diagnostic criteria for temporomandibular disorders (DC/TMD) for clinical and research applications: Recommendations of the International RDC/TMD Consortium Network\* and Orofacial Pain Special Interest Group. *J Oral Facial Pain Headache* 2014; 28: 6–27.
  66. Treede RD, Jensen TS, Campbell JN, et al. Neuropathic pain. Redefinition and a grading system for clinical and research purposes. *Neurology* 2008; 70: 1630–1635.
  67. Finnerup NB, Haroutounian S, Kamerman P, et al. Neuropathic pain: An updated grading system for research and clinical practice. *Pain* 2016; 157: 1599–1606.
  68. Svensson P, Baad-Hansen L, Pigg M, et al. Guidelines and recommendations for assessment of somatosensory function in oro-facial pain conditions – a taskforce report. *J Oral Rehabil* 2011; 38: 366–394.
  69. Eliav E, Gracely RH, Nahlieli O, et al. Quantitative sensory testing in trigeminal nerve damage assessment. *J Orofac Pain* 2004; 18: 339–344.
  70. Jääskeläinen SK. Clinical neurophysiology and quantitative sensory testing in the investigation of orofacial pain and sensory function. *J Orofac Pain* 2004; 18: 85–107.
  71. Jääskeläinen SK, Teerijoki-Oksa T, Virtanen A, et al. Sensory regeneration following intraoperatively verified trigeminal nerve injury. *Neurology* 2004; 62: 1951–1957.
  72. Teerijoki-Oksa T, Jääskeläinen S, Forssell K, et al. An evaluation of clinical and electrophysiologic tests in nerve

- injury diagnosis after mandibular sagittal split osteotomy. *Int J Oral Maxillofac Surg* 2003; 32: 15–23.
73. Teerijoki-Oksa T, Jääskeläinen SK, Forssell K, et al. Recovery of nerve injury after mandibular sagittal split osteotomy. Diagnostic value of clinical and electrophysiologic tests in the follow-up. *Int J Oral Maxillofac Surg* 2004; 33: 134–140.
  74. Svensson P, Baad-Hansen L, Drangsholt MT, et al. Neurosensory testing for assessment, diagnosis, and prediction of orofacial pain. In: Sessle BJ (ed.) *Orofacial pain: Recent advances in assessment, management, and understanding of mechanisms*. Washington DC: IASP Press, 2014, pp.143–164.
  75. Ziccardi VB, Drago J, Eliav E, et al. Comparison of current perception threshold electrical testing to clinical sensory testing for lingual nerve injuries. *J Oral Maxill Surg* 2012; 70: 289–294.
  76. Rolke R, Magerl W, Campbell KA, et al. Quantitative sensory testing: A comprehensive protocol for clinical trials. *Eur J Pain* 2006; 10: 77–88.
  77. Sarlani E, Farooq N and Greenspan JD. Gender and laterality differences in thermosensation throughout the perceptible range. *Pain* 2003; 106: 9–18.
  78. Aramideh M and Ongerboer d,V. Brainstem reflexes: Electrodiagnostic techniques, physiology, normative data, and clinical applications. *Muscle Nerve* 2002; 26: 14–30.
  79. Cruccu G, Iannetti GD, Marx JJ, et al. Brainstem reflex circuits revisited. *Brain* 2005; 128: 386–394.
  80. Ellrich J. Brain stem reflexes: Probing human trigeminal nociception. *News Physiol Sci* 2000; 15: 94–97.
  81. Kaube H, Katsarava Z, Kaufer T, et al. A new method to increase nociception specificity of the human blink reflex. *Clin Neurophysiol* 2000; 111: 413–416.
  82. Thygesen TH, Baad-Hansen L and Svensson P. Sensory action potentials of the maxillary nerve: A methodologic study with clinical implications. *J Oral Maxillofac Surg* 2009; 67: 537–542.
  83. Jääskeläinen SK, Teerijoki-Oksa T, Forssell K, et al. Intraoperative monitoring of the inferior alveolar nerve during mandibular sagittal-split osteotomy. *Muscle Nerve* 2000; 23: 368–375.
  84. Han SR, Yeo SP, Lee MK, et al. Early dexamethasone relieves trigeminal neuropathic pain. *J Dent Res* 2010; 89: 915–920.
  85. Finnerup NB and Jensen TS. Mechanisms of disease: Mechanism-based classification of neuropathic pain – a critical analysis. *Nat Clin Pract Neurol* 2006; 2: 107–115.
  86. Finnerup NB, Otto M, McQuay HJ, et al. Algorithm for neuropathic pain treatment: An evidence based proposal. *Pain* 2005; 118: 289–305.
  87. Finnerup NB, Attal N, Haroutounian S, et al. Pharmacotherapy for neuropathic pain in adults: A systematic review and meta-analysis. *Lancet Neurol* 2015; 14: 162–173.
  88. Demant DT, Lund K, Vollert J, et al. The effect of oxcarbazepine in peripheral neuropathic pain depends on pain phenotype: A randomised, double-blind, placebo-controlled phenotype-stratified study. *Pain* 2014; 155: 2263–2273.
  89. Eliav E and Benoliel R. Neuropathic orofacial pain mechanisms: Insights from human experimental studies. In: Sessle BJ (ed.) *Orofacial pain: Recent advances in assessment, management, and understanding of mechanisms*. Washington, DC: IASP Press, 2014, pp.415–434.
  90. Di Stefano G, La Cesa S, Truini A, et al. Natural history and outcome of 200 outpatients with classical trigeminal neuralgia treated with carbamazepine or oxcarbazepine in a tertiary centre for neuropathic pain. *J Headache Pain* 2014; 15: 34.
  91. Abrahamsen R, Baad-Hansen L and Svensson P. Hypnosis in the management of persistent idiopathic orofacial pain – clinical and psychosocial findings. *Pain* 2008; 136: 44–52.